Diagnostic and Interventional Imaging 104 (2023) 24–36

Review/*Gastrointestinal imaging*

Artificial intelligence: A review of current applications in hepatocellular carcinoma imaging

Anna Pellat[a,b,*], Maxime Barat[b,c], Romain Coriat[a,b], Philippe Soyer[b,c], Anthony Dohan[b,c]

[a] *Department of Gastroenterology and Digestive Oncology, Hôpital Cochin, AP-HP, 75014 Paris, France*
[b] *Université Paris Cité, 75006 Paris, France*
[c] *Department of Radiology, Hôpital Cochin, AP-HP, 75014 Paris, France*

ARTICLE INFO

Keywords:
Hepatocellular carcinoma
Artificial intelligence
Machine learning
Deep learning
Diagnosis
Treatment

ABSTRACT

Hepatocellular carcinoma (HCC) is the most common type of primary liver cancer and currently the third-leading cause of cancer-related death worldwide. Recently, artificial intelligence (AI) has emerged as an important tool to improve clinical management of HCC, including for diagnosis, prognostication and evaluation of treatment response. Different AI approaches, such as machine learning and deep learning, are both based on the concept of developing prediction algorithms from large amounts of data, or big data. The era of digital medicine has led to a rapidly expanding amount of routinely collected health data which can be leveraged for the development of AI models. Various studies have constructed AI models by using features extracted from ultrasound imaging, computed tomography imaging and magnetic resonance imaging. Most of these models have used convolutional neural networks. These tools have shown promising results for HCC detection, characterization of liver lesions and liver/tumor segmentation. Regarding treatment, studies have outlined a role for AI in evaluation of treatment response and improvement of pre-treatment planning. Several challenges remain to fully integrate AI models in clinical practice. Future research is still needed to robustly evaluate AI algorithms in prospective trials, and improve interpretability, generalizability and transparency. If such challenges can be overcome, AI has the potential to profoundly change the management of patients with HCC. The purpose of this review was to sum up current evidence on AI approaches using imaging for the clinical management of HCC.

© 2022 Société française de radiologie. Published by Elsevier Masson SAS. All rights reserved.

1. Introduction

Artificial intelligence (AI) refers to intelligence demonstrated by machines, as opposed to the natural intelligence of human beings. Indeed, the definition of intelligence itself is controversial, especially in medical imaging where AI refers to machine learning (ML) algorithms developed to improve the medical images analysis and to discover new biomarkers. ML includes multiple different techniques such as deep learning (DL) based on the concept of developing prediction algorithms from large amounts of data, or big data (Fig. 1). The era of digital medicine has led to a rapidly expanding amount of routinely collected health data (RCD) extracted from electronic health records or other types of sources. By leveraging this large-scale data, we can see how AI can be a powerful ally to human-driven medicine.

Various ML techniques have widely been used in medical studies [1,2]. Advances in the field of AI, primarily due to hardware advancements, have led to the development of DL, one of the most complex subset of ML, with multi-layered neural network algorithms, using techniques such as convolutional neural network (CNN) which has proven usefulness in the analysis of endoscopic images [3], radiological images [4], ophtalmological images [5] or histological samples [6,7]. Although AI has many applications in medicine, it also shows limitations.

Hepatocellular carcinoma (HCC), which usually occurs in the setting of liver cirrhosis, accounts for at least 80% of all primary liver cancers and is the third leading cause of cancer-related mortality worldwide [8]. Its incidence has been rising in the past years with highest incidences currently observed in Northern Africa, South-Eastern Asia and Eastern Asia [9]. With that in mind, populations at risk need life-time surveillance for early detection of HCC in order to access curative-intended treatments, which can be quite particularly challenging on a background of chronic liver disease. Despite some improvements in HCC treatments, overall survival is poor, especially in the metastatic setting.

Abbreviations: AI, Artificial intelligence; ANN, Artificial neural networks; AUC, Area under the curve; BCLC, Barcelona clinic liver cancer; CAD, Computer-aided diagnosis; CEUS, Contrast-enhanced ultrasound; CNN, Convolutional neural network; CT, Computed tomography; DL, Deep learning; HCC, Hepatocellular carcinoma; ICC, Intrahepatic cholangiocarcinoma; LI-RADS, Liver Imaging Reporting and Data System; LR, Logistic regression; ML, Machine learning; MRI, Magnetic resonance imaging; MVI, Microvascular invasion; RCD, Routinely collected health data; RF, Random forest; SVM, Support vector machine; TACE, Transcatheter arterial chemoembolization

* Corresponding author: anna.pellat@aphp.fr
E-mail address: anna.pellat@aphp.fr (A. Pellat).

https://doi.org/10.1016/j.diii.2022.10.001
2211-5684/© 2022 Société française de radiologie. Published by Elsevier Masson SAS. All rights reserved.

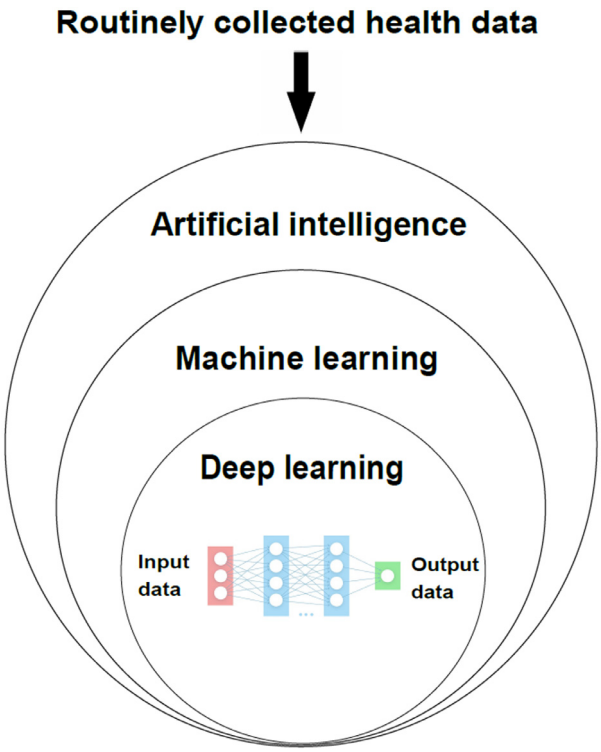

Fig. 1. Diagram illustrates the artificial intelligence process when using routinely collected health data.

HCC is a particular tumor to study with AI approaches because it shows specific imaging features that can sometimes be used to make a diagnosis, thus obviating the need for histopathological analysis. Therefore, various AI approaches have been developed over the years to try to help solve the aforementioned issues.

The purpose of this review was to sum up the recent evidence of AI approaches based on radiological modalities in the management of HCC, focusing on diagnosis and treatment.

2. Artificial intelligence approaches in medicine and imaging: what to keep in mind for a better understanding

The massive trove of RCD offers a great opportunity to develop AI-based models (Fig. 1). The optimal AI approach usually depends on the type and size of the medical data at hand as no model works best for all situations. ML has been increasingly applied in the field of radiology, where it is being studied in image diagnosis, organ segmentation, image quality improvement, medical report writing and to discover new biomarkers [10,11].

ML is based upon training of an algorithm on data (or training data). Unlike traditional techniques, ML does not rely on explicit rules, and does not consider an *a priori* type of relationship between potential predictors. It learns the implicit features, or patterns, of the data during training. This allows for the model to generalize to unseen data and to be leveraged as a predictive tool. Supervised ML relies on labeled data, whereas unsupervised techniques leverage unlabeled data. Different ML techniques, such as logistic regression (LR), decision tree, random forest (RF), support vector machine (SVM), and k-nearest neighbor have all been used in various medical studies [1,2]. ML models will be very well adapted to tabular health data, such as a patient's clinicopathological or laboratory parameters.

DL is a subset of ML, based on artificial neural networks (ANN), processing large amounts of data through multiple layers of artificial neurons. The architecture of neural networks is inspired by the complex architecture of the human brain and its biological networks of neurons. Over the years, deep neural nets have proven to be effective technology for processing and understanding patterns in very large datasets of images, texts and even audio. This is due to these models' ability to automatically discover patterns in the raw data, where other ML techniques would need to be provided with an explicit set of features [10]. CNN, which are commonly used in radiological AI approaches and on image data in general, are based on convolutional layers of neural nets.

On the basis of access to a rapidly expanding quantity of radiology images and progress in development of AI models, a new analysis approach has emerged in the field of imaging: radiomics. Radiomics allows for the extraction of a great amount of quantitative data from medical images to identify specific features quantifying tumor phenotypic characteristics. Radiomics is not in extensive use in clinical practice because of the lack of externally validated robust models and the need for manual segmentation of tumors that limits its development. However, progress in the field of AI could contribute in increasing the clinical applicability and generalizability of radiomics in the future [12].

3. Artificial intelligence approaches for the diagnosis of hepatocellular carcinoma

3.1. Background

Current international guidelines recommend surveillance for early HCC detection in high-risk populations [13–15]. In these patients, ultrasonography is the most appropriate test for surveillance [13]. Ultrasound is subject to high degree of dependence on operator experience, equipment quality and patient morphology, all of which can impact the quality of the exam. Hence, it is not always easy to detect focal liver lesions, especially in cirrhotic patients, or to characterize the encountered lesion. According to meta-analysis results, the sensitivity for detection of HCC of conventional ultrasound is only 59% to 78% [16,17]. Different ultrasound modalities have emerged in order to improve sensibility and specificity, such as contrast-enhanced ultrasound (CEUS) which has improved the sensibility for HCC detection [16,17].

Since 2001, non-invasive imaging diagnosis of HCC in the setting of cirrhosis has been accepted [13–15]. Multiphasic computed tomography (CT) and magnetic resonance imaging (MRI) are the only two validated contrast-enhanced image techniques for the diagnosis of HCC [13–15]. In practice, when a new liver lesion is found by ultrasound, patients will be referred for further imaging with CT or MRI. Nevertheless, the radiological diagnosis of HCC is not always simple as there is a high prevalence of atypical radiological features or the existence of other malignant tumors, such as intrahepatic cholangiocarcinoma (ICC), that can mimic HCC. Therefore, patients with liver lesions presenting atypical features will either need histological confirmation or close follow-up. In this context, various AI models have been constructed to help increase the non-invasive diagnosis accuracy of HCC. We will describe studies focused on diagnosis with AI approaches using radiological parameters. Mentioned studies are summarized in Tables 1, 2 and 3.

3.2. Artificial intelligence based on ultrasound data

3.2.1. Improving detection of focal liver lesions and/or distinction from cirrhotic liver

To assess and differentiate different stages of liver disease, Bharti et al. proposed a model combining three AI classifiers using data from ultrasound images: the classification accuracy of the ensemble model was 96.6% [18]. More recently, Brehar et al. showed that a CNN model, based on ultrasound images from two different ultrasound machines (two datasets), outperformed conventional ML

Table 1
Summary of studies evaluating artificial intelligence approaches based on ultrasound imaging for the diagnosis of hepatocellular carcinoma.

Author, year [Ref.]	Study outcome	Type and size of the training and/or test and/or validation set (s) (n)	Artificial intelligence approach (es)	Validation method(s) *as described in each study*	Performance value(s) (*best values unless stated otherwise)*	Sensitivity (%)/Specificity (%) (*best values unless stated otherwise)*
Ultrasound imaging						
Virmani J, 2014 [20]	Characterization of focal liver lesions (including HCC)	108 images	NNE	Internal validation and testing	Accuracy: 95%	N.R.
Bharti P, 2018 [18]	Distinction of different liver diseases (from normal liver to HCC)	189 images from 94 patients: 48 normal liver, 50 chronic liver, 50 cirrhosis, 41 HCC	Ensemble model with 3 classifiers: k-NN SVM Rotation forest	Internal validation	Accuracy: 96.6%	95.5–96.9/98.0–99.8
Schmauch B, 2019 [21]	Detection and characterization of focal liver lesions as benign (cyst, FNH and angioma) *vs.* malignant (HCC, metastasis)	Training set: 367 images from 367 patients with radiological reports (109 with focal liver lesions) Test set: 177 patients	CNN	Internal validation and testing	Training set: Mean AUC: 0.935 for detection; Mean AUC: 0.916 for characterization Test set: Mean AUC: 0.891 for detection	N.R.
Brehar R, 2020 [19]	Distinction between HCC and cirrhosis	2 datasets: 200 patients with 823 images 68 patients with 508 images (80% for training and 20% for testing)	CNN	Internal validation and testing	Accuracy 84.8–91%, AUC 0.91–0.95	86.79–94.37/82.95–88.38
Yang Q, 2020 [22]	Characterization of focal liver lesions (as benign *vs.* malignant).	Available pathological results for liver lesions. Training set: 16500 images/1446 patients Internal validation set: 4125 images/369 patients External validation set: 3718 images/328 patients	CNN: 3 models with and without background and clinical parameters	Internal and external validations	Training: AUC: 0.765–0.925 Internal validation: AUC: 0.859–0.966 External validation: AUC: 0.750–0.924	N.R.
Mao B, 2021 [23]	Characterization of primary and secondary malignant liver lesions	114 patients (pathologically confirmed liver cancer) Training set: 91 patients Test set: 23 patients	LR k-NN MLP RF SVM	Internal validation and testing	Mean accuracy: 72.9–84.3%, Mean AUC: 0.737–0.816 *(average values for all models)*	77.5–86.8/66.7–88.0 (*average values for all models)*

(*continued on next page*)

Table 1 (*Continued*)

Author, year [Ref.]	Study outcome	Type and size of the training and/or test and/or validation set (s) (n)	Artificial intelligence approach (es)	Validation method(s) *as described in each study*	Performance value(s) (*best values unless stated otherwise)*	Sensitivity (%)/Specificity (%) (*best values unless stated otherwise)*
Ren S, 2021 [24]	Prediction of pathological grading of HCC	193 patients (pathologically confirmed HCC) Training set: 128 Test set: 32 External validation set: 33	SVM 3 models: ultrasomics features, clinical factors alone and combined	Internal validation, testing and external validation	Training: AUC: 0.788–0.977, Accuracy: 74.22–92.19% Test: AUC: 0.720–0.874, Accuracy: 68.75–84.38% External validation: AUC: 0.770–0.849, Accuracy: 66.67–81.82%	Training: 64.71–90.20/80.52–93.51 Test: 57.14–85.71/72.00–84.00 External validation: 75.00/61.90–85.71
Ren S, 2021 [25]	Differentiation between HCC and ICC	226 patients (pathologically confirmed HCC or ICC) Training set: 149 Test set: 38 External validation set: 39	SVM 3 models: ultrasomics features, clinical factors and combined	Internal and external validation	Training: AUC: 0.840–0.975, Accuracy: 70.47–89.26 Test: AUC: 0.711–0.936, Accuracy: 71.05–86.84 External validation: AUC: 0.730–0.874, Accuracy 69.23–87.18	Training: 77.42–96.77/68.64–87.29 Test: 70.00–90.00/71.43–85.71 External validation: 66.67–88.87/66.67–86.67
Contrast-enhanced ultrasound imaging						
Ta CN, 2018 [27]	Characterization of focal liver lesions as benign *vs.* malignant	106 lesions	SVM ANN	Internal validation	AUC: 0.829–0.883 Accuracy: 80.0–81.1%	N.R.
Guo LH, 2018 [29]	Differentiating benign from malignant liver lesions	93 lesions: 47 malignant and 46 benign	MKL	Internal validation	Accuracy: 90.41%	93.56/86.89
Huang Q, 2020 [28]	Differentiation between atypical HCC and FNH	257 images	SVM	Internal validation	AUC: 94.40%	94.76/93.62
Wang W, 2021 [30]	Preoperative histological grading	235 HCC lesions: 65 high grade and 170 low grade lesions	SVM 3 models: ultrasomics features, clinical factors alone and combined	Internal and external validation	AUC: 0.665–0.785	N.R.

ANN: Artificial neural network; AUC: Area under the curve; CNN: Convolutional neural network; FNH: Focal nodular hyperplasia; HCC: Hepatocellular carcinoma; ICC: Intrahepatic cholangiocarcinoma; k-NN: k-nearest neighbor; LR: Logistic regression; MKL: Multiple kernel learning; MLP: Multilayer perceptron; NNE: Neural network ensemble; N.R.: Not reported; RF: Random forest; SVM: Support vector machine

Table 2
Summary of studies evaluating artificial intelligence approaches based on computed tomography for the diagnosis of hepatocellular carcinoma.

Author, year [Ref.]	Study outcome	Type and size of the training and/or test and/or validation set (s) (n)	Artificial intelligence approach(es)	Validation method(s) *as described by each study*	Performance values (*best values unless stated otherwise*)	Sensitivity (%)/Specificity (%) (*best values unless stated otherwise*)
Characterization of liver lesions						
Yasaka K, 2018 [35]	Characterization of liver lesions: 1/classification in five categories 2/malignant (HCC and non-HCC liver cancers) vs indeterminate and benign lesions (hemangiomas and cysts)	Training set: 460 patients Test set: 100 patients CT images from non-contrast-enhanced, arterial, and delayed phases	CNN	Internal validation and testing	1/ Classification: Training: Median accuracy 95–97% Test: Median accuracy 48–84% 2/ Malignant vs the rest: Test: Median AUC 0.61–0.92	1/ Classification: Test: Se: 11–100
Khan A A, 2019 [32]	Characterization of liver lesions: malignant versus benign (hemangioma)	179 patients: 98 benign and 81 malignant lesions	SVM k-NN Ensemble classifier	Internal validation and testing	Accuracy: 96.6–98.3%	Sp for HCC: 94.23–97.03
Todoroki Y, 2019 [39]	Characterization of focal liver lesions (five categories)	89 patients	CNN	Internal validation and testing	N.R.	Se: 79–100
Li J, 2019 [37]	Classification of nodular, diffuse and massive HCC	165 CT images: 46 diffuse tumors, 43 nodular tumors And 76 massive tumors	ANN SVM CNN	Internal validation and testing	Average AUC: 0.957–0.990, Average accuracy: 92.6–98.4% *(average values for all three models)*	N.R.
Mokrane FZ, 2020 [31]	Characterization of indeterminate liver lesions in cirrhotic patients (HCC and non-HCC)	Training set: 106 patients Calibration set: 36 patients External validation set: 36 patients (77% of biopsy-confirmed HCC)	Radiomics k-NN RF SVM	Internal and external validation	Training: AUC : 0.79–0.81 Calibration: AUC 0.67–0.69 External validation: AUC: 0.66	Training: 81/72 External validation: 70/54
Shi W, 2020 [36]	Differentiation of HCC from other focal liver lesions	342 patients with 449 lesions (194 HCC) Training set: 359 lesions Test set: 90 lesions	MP-CDN (3 models)	Internal validation and testing	Accuracy 81.1–85.6%, AUC 0.862–0.925	74.4–92.3/72.5–94.1
Zhou J, 2020 [38]	Characterization of liver lesions: 1/malignant (HCC, ICC and metastasis) versus benign lesions (cyst, hemangioma, and FNH) 2/classification in six categories of liver lesions	616 focal liver lesions	CNN	Internal validation and testing	1/Detection: Average precision of 82.8% 2/Classification: Binary classification: Accuracy: 82.5%, AUC: 0.921 Six-class classification: Accuracy: 73.4%, AUC: 0.766–0.983	2/Classification: Binary classification: 76.6–88.4/76.6–88.4 Six-class classification: 46.6–93.1/91.9–98.6
Mao B, 2020 [34]	Grading of HCC	Training set: 237 patients with HCC Test set: 60 patients with HCC	Radiomics eXtreme Gradient Boosting	Internal validation and testing	Training: AUC: 0.6915–0.9964, Accuracy: 61.18–97.05% Test: AUC: 0.6128–0.8014, Accuracy: 48.3–70.00%	Training: 60.67–95.51/51.35–80.41 Test: 43.48–65.22/37.84–81.08
Ponnoprat D, 2020 [40]	Differentiation between HCC and ICC	187 HCC and 70 ICC lesions	CNN SVM	Internal validation	Accuracy 88%, TPR for HCC 95.18%, TPR for ICC 69.44%	N.R.
Krishan A, 2021 [33]	1/Detection and 2/classification of malignant liver lesions (HCC and secondary liver lesions)	1638 CT scans	Several individual classifiers and multi-level ensemble	Internal validation	Detection: Accuracy 98.39–100%, AUC 0.99–1.00 Classification: Accuracy 76.38–87.01%, AUC 0.77–0.99	N.R.
Liver and/or tumor segmentation						
Li W, 2015 [41]	Tumor segmentation in the liver	26 portal phase enhanced CT images	CNN	Internal validation and testing	Precision of 82.67 ± 1.43%	N.R.
Vivanti R, 2017 [46]	Detection and segmentation of new liver tumors	246 tumors (97 new tumors)	CNN	Internal validation	TR 72–86% for detection	N.R.

(*continued*)

Table 2 (*Continued*)

Author, year [Ref.]	Study outcome	Type and size of the training and/or test and/or validation set (s) (n)	Artificial intelligence approach(es)	Validation method(s) *as described by each study*	Performance values (*best values unless stated otherwise)*	Sensitivity (%)/Specificity (%) (*best values unless stated otherwise)*
Sun C, 2017 [42]	Tumor segmentation in the liver	CT images taken from 2 databases Training set: 3809 images (2785 +1024)	FCN	Internal validation and testing	VOE 15.6–38.2 VOE 8.1–19.1 *for each data set*	N.R.
Chlebus G, 2018 [43]	Tumor segmentation in the liver	LiTS challenge dataset: 130 training CT, 70 test CT	FCN and RF	Internal validation and testing	Mean dice score 0.69	N.R.
Chen L, 2019 [44]	Tumor segmentation in the liver	LiTS challenge dataset: 130 training CT, 70 test CT	FCN	Internal validation and testing	Mean dice score 0.684	N.R.
Chen WF, 2020 [45]	Tumor segmentation in the liver	LiTS challenge dataset: 130 training CT, 70 test CT	SED	Internal validation and testing	Accuracy: 0.992; AUC: 0.95, Dice score: 0.75	N.R.

ANN: Artificial neural networks; AUC: Area under the curve; CNN: Convolutional neural network; FCN: Fully convolutional network; FNH: Focal nodular hyperplasia; HCC: Hepatocellular carcinoma; ICC: Intrahepatic cholangiocarcinoma; k-NN: k-nearest neighbor; LiTS: Liver tumor segmentation; MP-CDN: Multiphase convolutional dense network; N.R.: Not reported; RF: Random forest; SED: Successive Encoder-Decoder; Se: Sensitivity; Sp: Specificity; SVM: Support vector machine, TPR: True positive ratio; VOE: Volumetric overlap error.

models (SVM, RF, multi-layer perceptron and AdaBoost) in differentiating HCC from cirrhotic parenchyma [19].

3.2.2. Characterization of focal liver lesions

Virmani et al. developed a neural network ensemble-based computer-aided diagnosis (CAD) that could distinguish normal liver from four different liver lesions with an accuracy of 95% [20]. Diagnosis for included liver lesions was confirmed by experienced participating radiologists, clinical follow-up and other associated findings [20]. Later, Schmauch et al. used a dataset provided by a French radiology public challenge to design a supervised DL model which could detect focal liver lesions and characterize them as benign or malignant with a mean area under the curve (AUC) of 0.935 and 0.916, respectively [21]. Considering the rather small number of images used for training, this model would need validation [21]. More recently, another CNN model was constructed by using a large multicentric database of ultrasound images along with background and clinical parameters [22]. The AUC for distinguishing benign from malignant lesions was 0.924 in the external validation cohort [22]. The combined model showed better accuracy than judgment by clinical radiologists or contrast-enhanced CT, but was slightly inferior to MRI [22]. In one study, radiomic features were extracted from ultrasound images and used for the development of various ML-based models to distinguish primary from secondary liver cancer; in this study, the LR model outperformed other ML models in this work [23]. In another work, a combined SVM-based ultrasomics model could predict pathological grading of HCC with an AUC of 0.874 in the test set [24]. Finally, another combined model could differentiate between HCC and ICC with good performances [25]. In these last four studies, liver lesions were pathologically confirmed and used as standard reference. However, the use of ultrasound for radiomics models raises some issues in terms of repeatability [26].

Ta et al. showed that a ML-based CAD using CEUS data could classify lesions as benign or malignant with a similar accuracy than expert radiologists and could even improve the physician's accuracy [27]. Huang et al. constructed a SVM-based CAD model which could differentiate atypical HCC and focal nodular hyperplasia using CEUS data with an average accuracy of 94.4% compared with pathology reports and subsequent clinical follow-up [28]. Guo et al. demonstrated that a multiple-kernel learning-based model could increase the sensitivity, specificity, and overall accuracy of CEUS for detecting HCC [29]. Finally, a combined ultrasomics-based model could discriminate HCC pathological grading with an AUC of 0.720 [30].

Table 1 summarizes the results of studies evaluating AI approaches based on ultrasound data for the diagnosis of HCC.

3.3. Artificial intelligence based on computed tomography data

3.3.1. Characterization of focal liver lesions

Mokrane et al. built a radiomics signature, based on 13 920 CT imaging features, that achieved AUCs of 0.81 and 0.66 for distinguishing HCC from non-HCC lesions in cirrhotic patients in the training and external validation sets, respectively [31]. Biopsy was positive for HCC in 77% of patients evaluated in this study [31]. Khan et al. developed an SVM-based tool for classification of liver tumors as benign or malignant with an accuracy of 98.3% [32]. One study used CT data to develop several ML-based models that showed good performances for the detection and characterization of malignant liver lesions [33]. In another study, clinical parameters and contrast enhanced CT-based radiomics were used either separately or combined to develop gradient boosting-based models for pathological grading of HCC: the combined model showed the best performance with an AUC of 0.8014 in the test set [34].

Several CNN-based models using CT images were also developed. CT images over three phases were used to construct a CNN model for distinguishing malignant liver lesions from indeterminate and benign liver lesions: the median AUC was 0.92 in the test set [35]. Another team compared the performance of a tree-phase contrast-enhanced CT protocol combined with a DL model, to a four-phase CT protocol, for distinguishing HCC from other focal liver lesions [36]. Combination of the DL approach with a triphasic CT protocol without pre-contrast yielded similar diagnostic accuracy (85.6%) to a four-phase CT protocol (83.3%; $P = 0.765$) [36]. These findings suggest that skipping the pre-contract phase might not compromise accuracy while reducing a patient's radiation dose. Another team built a CAD system with three different classifiers to help diagnose different types of HCC (nodular, diffuse and massive): the CNN classifier was superior to both ANN and SVM classifiers for classification of nodular and massive tumors but not diffuse tumors [37]. In another recent work, a new CNN-based CAD was developed to automatically detect and classify focal liver lesions as benign or malignant: the classification performance of the model was placed between a junior and senior

Table 3
Summary of studies evaluating artificial intelligence approaches based on magnetic resonance imaging for the diagnosis of hepatocellular carcinoma.

Author, year [Ref.]	Study outcome	Type and size of the training and/or test and/or validation set (s) (n)	Artificial intelligence approach(es)	Validation method (s) *as described by each study*	Performance values (*best values unless stated otherwise*)	Sensitivity (%)/Specificity (%) (*best values unless stated otherwise*)
Jansen M, 2019 [49]	Classification among five different focal liver lesions	95 patients: 125 benign lesions (adenoma, cyst, hemangioma) and 88 malignant lesions (HCC, metastases)	Extremely randomized trees classifier	Internal validation	Overall accuracy 77%	62–93/56–93
Hamm C, 2019 [50]	Classification of six different focal liver lesions (adenoma, cyst, FNH, HCC, ICC, metastases)	494 liver lesions: Training set: 434 Test set: 60	CNN	Internal validation and testing	Training: Accuracy 98.7% Test: Accuracy 91.9%	Training: 60–100/94–100 Test:89–99/97–100
Oyama A, 2019 [56]	Classification of focal liver lesions	150 liver lesions (50 HCC, 50 metastases, 50 hemangiomas)	Radiomics LR and XGboost	Internal validation and testing	Accuracy: 52–85% AUC: 0.45–0.89	18–86/30–94
Trivizakis E, 2019 [55]	Classification of malignant liver lesions: primary vs secondary	134 patients	2D and 3D fully CNN and SVM	Internal validation and testing	Accuracy: 65–93.9 AUC: 53–93.7	67–95/39–92.3
Kim J, 2020 [47]	HCC detection	Training set: 455 patients External validation set: 45 patients	CNN	Internal validation, testing and external validation	Training: AUC: 0.97 Validation: AUC: 0.90	Training: 94/99 Validation: 87/93
Zhen SH, 2020 [51]	Classification of focal liver lesions	Training set: 1210 patients External validation set: 201 patients	CNN (various models: seven-way, binary and three-way classifiers)	Internal validation, testing and External validation	External validation: AUC: 0.841–0.989	External validation: 40.5–100/67.3–100
Wu Y, 2020 [53]	Distinction between LI-RADS 3 and LI-RADS 4/5 tumors	89 liver lesions (59 patients) MR images acquired at three time points (pre-contrast, arterial and washout phase)	CNN	Internal validation and testing	Accuracy: 76.7–90.0% AUC: 0.90–0.95	Se: 75.6–88.9
Liang W, 2020 [57]	Classification of three focal liver lesions (Epithelioid Angiomyolipoma, HCC and FNH)	170 patients with CT 137 patients with MRI	Radiomics RF ANN RR	Internal validation and testing	CT model: Training: 0.861–0.996 Test: 0.731–0.879 MRI model Training: 0.987–0.999 Test: 0.736–0.925	–
Bousabarah K, 2021 [48]	1/HCC detection and 2/segmentation	174 patients with 231 lesions	CNN RF	Internal validation and testing	1/Detection Validation: Dice score: 0.49 Test: Dice score: 0.48 2/Segmentation Validation: Dice score: 0.64 Test: Dice score: 0.68	1/Detection Validation: Se 55–73 Test: Se 66–75
Oestmann P M, 2021 [52]	Differentiation between HCC and non-HCC lesions	118 patients with 150 lesions ((93 HCC and 57 non-HCC) Training set: 140 Test set: 10	CNN	Internal validation and testing	Training: Accuracy: 94.1% Test: Accuracy: 87.3%	Test: Classification of HCC: 92.7%/82.0% Classification of non-HCC: 82.0%/92.7%

ANN: Artificial neural networks; AUC: Area under the curve; CNN: Convolutional neural network, CT: Computed tomography; FNH: Focal nodular hyperplasia; HCC: Hepatocellular carcinoma; ICC: Intrahepatic cholangiocarcinoma; LI-RADS: Liver Imaging Reporting and Data System. LR: Logistic regression; MRI: Magnetic resonance imaging; RF: Random forest; RR: Ridge regression; SVM: Support vector machine.

physician's evaluation [38]. Similarly, multiphasic CT images extracted from a smaller group of patients were used to develop a CNN-based model to detect and classify five different focal liver lesions [39]. Finally, another study constructed a two-step method for distinguishing HCC and ICC with a classification accuracy of 88% [40].

3.3.2. Liver and tumor segmentation

Liver and tumor (including HCC and other liver malignancies) segmentation are of great importance to assess the tumor burden, detect early recurrence, extract radiomic features and for planning the ideal treatment. However, manual segmentation is not always easy, especially in the context of diffuse or small lesions.

Li et al. proposed a CNN-based model using 26 CT images which could perform liver tumors segmentation with a precision of 82.67% [41]. Later, Sun et al. designed and validated a fully CNN which achieved high accuracy for segmentation of liver tumors [42]. Since 2017, the Liver Tumor Segmentation Challenge calls upon investigators to develop AI-based algorithms for automatic liver tumors segmentation using a multinational dataset of 200 CT scans (130 training CT scans, 70 test CT scans) (https://competitions.codalab.org/competitions/17094). Various works using this dataset have been published over the years [43–45]. Up to this day, 280 different teams

have already participated to the challenge, and top-scoring methods used fully CNN or U-nets that separately segmented the liver and liver lesions. Currently the best-scoring algorithm achieved a dice score of 0.825 for lesion segmentation. While these findings are promising, there was notable variability in both the imaging characteristics of liver tumors and in their delineation, underscoring the need for universal and standardized methods for liver tumor segmentation. Vivanti et al. described a segmentation-based CNN model for automatic detection of recurrence during follow-up [46]. The method could achieve a true positive rate of 86% for lesions >5 mm [46].

Table 2 summarizes the results of studies evaluating AI approaches based on CT data in the field of HCC.

3.4. Artificial inteligence based on magnetic resonance imaging data

Due to difficult access to manual MRI annotations as well as other technical limitations, AI approaches have been less frequently applied to MRI imaging of HCC and most of published studies have been conducted in rather small populations. Table 3 summarizes the results of studies evaluating AI approaches based on MRI data in the field of HCC.

3.4.1. Improving detection

In a multicenter retrospective study, a CNN-based model developed in 455 patients achieved 87% sensitivity and 93% specificity for the detection of HCC in the external validation dataset (45 patients) [47]. Notably, the model surpassed less experienced radiologists' performance in the diagnosis of small HCC lesions [47]. More recently, in a retrospective single-center study, a CNN-based model using multiphasic contrast-enhanced MRI data could automatically detect and delineate HCC with sensitivities of 73/75% (validation/test) [48]. Mean Dice scores between automatically detected lesions using the model and corresponding manual segmentations were 0.64/0.68 (validation/test) [48].

3.4.2. Characterization of focal liver lesions

Jansen et al. developed a model combining clinical data and MRI-based features which could distinguish HCC from other malignant or benign lesions with a sensitivity of 73% despite a specificity of 56% [49]. In addition, Hamm et al. also developed a CNN-based model that could successfully classify six different liver lesions with an overall accuracy of 92% [50]. More recently, Zhen et al. developed and externally validated various CNN-based models incorporating both enhanced and unenhanced MR images and clinical data from 1210 patients with liver tumors [51]. This DL system demonstrated excellent performance for classifying liver tumors on par with that observed for three experienced radiologists, including the combined model with unenhanced MR images, suggesting that, with further validation, these models may allow patients to avoid contrast agent injection and its complications [51]. Another recent study developed a CNN-based model using multiphasic MR images of patients with histologically proven liver lesions: the model was trained with a combination of images that met the Liver Imaging Reporting and Data System (LI-RADS) criteria for definitive HCC (LIRADS 5/typical) and with images that did not (atypical) and aimed to distinguish between HCC and non-HCC lesions [52]. Sensitivities/specificities for HCC and non-HCC lesions were 92.7%/82.0% and 82.0%/92.7%, respectively [52]. Similarly, another CNN-based model also showed high accuracy for distinguishing between LI-RADS 3 and LIRADS 4/5 liver lesions [53]. In addition to developing a focal liver lesion classifier, Wang et al. developed a proof-of-concept prototype for the automatic identification, mapping, and scoring of radiological features within a DL system, enabling radiologists to interpret elements of decision-making behind classification decisions [50,54]. With the need for further refinement and validation, interpretable and transparent DL systems could one day be used to improve standardized HCC reporting systems and thereby clinical outcomes. Of note, a CNN-based model using diffusion-weighted MRI could distinguish between primary liver cancer and liver metastasis with high accuracy [55]. Finally, radiomics approaches have also been applied to MRI for classification of liver lesions [56,57].

4. Artificial intelligence approaches to evaluate prognostication, treatment response and survival in hepatocellular carcinoma

4.1. Background

In the context of great individual variability between patients with HCC, the development of robust prognostic scoring systems is key to improve patient risk stratification in order to optimize treatment strategies and assess their effects. Here, AI can play a key role. Several DL algorithms have been developed to help predict response to a specific treatment by analyzing tumor characteristics, such as morphological features, which have a major impact on patient prognosis. By doing so, the idea is to select the best treatment option for patients. Mentioned studies will be summarized in Table 4.

4.2. Hepatic transplantation

Only one study has assessed the risk of HCC recurrence after liver transplantation using an AI model based on CT imaging [58]. The radiomics nomogram based on a combined model (radiomics signature and clinical risk factors) showed good predictive performance for recurrence-free survival with a C-index of 0.785 in the training dataset and 0.789 in the validation dataset [58].

4.3. Surgical resection

Microvascular invasion (MVI), defined as the presence of micrometastatic HCC emboli within the vessels of the liver, is a critical determinant of early recurrence and survival [59]. Three different groups developed radiomics-based models using CT images which could predict preoperative MVI with good performances, especially when combined with clinical factors [60–62]. Regarding MRI, three teams developed CNN-based models which could also predict MVI with high accuracies, including one that used diffusion-weighted MRI [63–65]. Finally, a radiomics model based on grayscale ultrasound images also showed promising results for the prediction of MVI [66].

Ji et al. combined several clinical and biological features (available before surgery) and radiomics signatures to assess the risk of HCC recurrence after surgical resection [67]. The preoperative model, as well as the postoperative model which also included pathological results, both outperformed conventional outcome prediction scores such as the Barcelona clinic liver cancer (BCLC) stage [67]. The models were also externally validated [67].

4.4. Transarterial chemoembolisation

Transcatheter arterial chemoembolization (TACE) is the treatment of choice for intermediate stage B HCC in the BCLC classification [13–15,68]. Several studies have investigated the ability of AI methods to predict response to TACE in patients with advanced HCC. Morshid et al used two CNN to extract CT image features that were then used as RF inputs after radiomics processing. They achieved a prediction accuracy rate of 74.2% using a combination of the BCLC stage plus quantitative image features *vs.* 62.9% using the BCLC stage alone [69]. Using residual CNN, Peng et al. trained (562 patients) and externally validated (89 and 138 patients) an algorithm yielding an AUC of at least 0.94 for prediction of complete or partial response and stable or progressive disease after TACE [70]. ML and DL techniques were both

Table 4
Summary of studies evaluating artificial intelligence approaches based on imaging for the prognostication and treatment of hepatocellular carcinoma.

Author, year [Ref.]	Study outcome	Type and size of the training and/or test and/or validation set (s) (n)	Artificial intelligence approach(es)	Validation method(s) *as described by each study*	Performance value (s) (*best values unless stated otherwise*)	Sensitivity (%)/Specificity (%) (*best values unless stated otherwise*)
Computed tomography						
Guo D, 2019 [58]	Recurrence-free survival after liver transplantation	130 patients Training set: 93 Validation set: 40	Radiomics LASSO ± clinical data	Internal validation	Training: C-index of 0.785 Validation: C-index of 0.789 *Results for combined model with clinical data*	N.R.
Ma X, 2019 [61]	Microvascular invasion prediction	157 patients with HCC (Training set, 110/Validation set: 47)	Nine different models with radiomics ± clinical data	Internal validation	Training: Accuracy: 67.3–83.6, AUC: 0.703–0.876 Validation: Accuracy: 46.8–80.9, AUC: 0.490–0.801	Training: 51.4–97.3/57.5–93.2 Validation: 38.9–94.4/37.9–94.4
Xu X, 2019 [62]	Microvascular invasion prediction and survival	495 patients with operated HCC (Training set, 350/Test set, 145)	Radiomics with clinical data LR	Internal validation and testing	Training: AUC: 0.909, Accuracy: 80% Test: AUC: 0.889, Accuracy: 82.8%	Training: 88.0/76.8 Test: 89.8/79.2
Ji GW, 2019 [67]	Prediction of HCC recurrence after resection *(results of the preoperative model are shown)*	Training set: 210 patients Internal validation: 107 patients External validation: 153 patients	RSF MRMR	Internal and External validation	Training: C-statistic: 0.748 Internal validation: C-statistic: 0.781 External validation: C-statistic: 0.733	N.R.
Morshid A, 2019 [69]	Prediction of response to TACE	105 patients	CNN RF (*model combined with clinical data*)	Internal validation	Accuracy: 74.2%, AUC: 0.73	N.R.
Shan Q-Y, 2019 [79]	Prediction of early recurrence of HCC after curative resection or ablation	156 patients (Training set, 109/External validation set, 47)	LASSO LR models	Internal and external validation	Validation: AUC: 0.61–0.79	N.R.
Peng J, 2020 [70]	Prediction of response to TACE	Training set: 562 patients Two external validation sets: 89+138 patients	Residual CNN	Internal and external validation	External Validation sets AUCs: >0.94, Accuracy: 82.8–85.1%	N.R.
Jiang Y-Q, 2020 [60]	Microvascular invasion prediction	405 patients Training set: 324 Validation set:81	Radiomics ± clinical parameters Gradient boosting CNN (4 models)	Internal validation	Training: AUC: 0.900–0.980 Validation: AUC: 0.875–0.906, Accuracy: 80.2–85.2%	Validation: 65.9–93.2/75.7–97.3
Liu Q-P, 2020 [71]	1/ Microvascular invasion prediction and 2/Prediction of prognostic risk factors in HCC treated with TACE	494 patients operated 243 receiving TACE	RF SVM	Internal validation and testing	1/ Microvascular invasion prediction Training: 0.84 Testing: 0.79 2/Prediction of prognostic risk factors in HCC treated with TACE: C-index of 0.733 for overall survival	N.R.
Zhang L, 2020 [72]	Prediction of response to TACE and sorafenib	201 patients (Training set, 120/External validation set, 81 patients)	CNN	External validation	Training: 0.664–0.739 External validation: 0.679–0.730	N.R.
An C, 2020 [78]	Local tumor progression after MWA	141 patients with HCC	CNN	No validation	AUC: 0.728	N.R.

(*continued*)

Table 4 (*Continued*)

Author, year [Ref.]	Study outcome	Type and size of the training and/or test and/or validation set (s) (n)	Artificial intelligence approach(es)	Validation method(s) *as described by each study*	Performance value (s) (*best values unless stated otherwise*)	Sensitivity (%)/Specificity (%) (*best values unless stated otherwise*)
Ultrasound imaging						
Dong Y, 2020 [66]	Microvascular invasion prediction	322 patients with operated HCC (Training set, 221/Test set, 101)	Radiomics +/- clinical data RF (2 classifiers)	Internal validation	AUC: 0.680–0.806 AUC: 0.744 with clinical data and classifier 1	33.3–83.8/53.1–92.9 (without clinical data); 89.2–94.6/32.8–48.4 with clinical data and classifier 1
Liu D, 2020 [76]	Prediction of response to TACE	130 patients Training set: 89 patients Validation set: 41 patients	Radiomics CNN	Internal validation	Training: AUC: 0.82–0.98, Accuracy: 78–98% Validation: AUC: 0.80–0.93, Accuracy: 80–90%	Training: 78.6–98.2/74.2–96.7 Validation: 82.1–89.3/73.3–92.3
Oezdemir I, 2020 [75]	Prediction of response to TACE	36 patients	Distance weighted discrimination method	Internal validation	Accuracy: 86%	89/82
Magnetic resonance imaging						
Zhang F, 2018 [74]	Liver tissue classification after TACE	20 patients	Auto-context-based CNN	Internal validation	Dice score: 0.63–0.77	N.R.
Abajian A, 2018 [73]	Prediction of response to TACE	36 patients	LR RF	Internal validation	Accuracy: 78%	62.5/82.1
Song D, 2021 [63]	Microvascular invasion prediction	601 patients with HCC (Training set, 461 patients/Testing set, 140 patients)	CNN (*models +/- clinical data*)	Internal validation and testing	Training: AUC: 0.764–0.934, Accuracy: 0.727–0.871 Testing: AUC: 0.731–0.931, Accuracy: 0.671–0.886	Training: 66.7–84.5/76.3–86.1 Testing: 64.7–88.2/68.5–88.8
Zhang Y, 2021 [64]	Microvascular invasion prediction	237 patients Training set: 158 patients Internal validation set: 79 patients	RF	Internal validation	Training: AUC: 0.81 Validation: AUC: 0.72	Training: 69/79 Validation: 55/81
Wang G, 2021 [65]	Microvascular invasion prediction	97 patients with 100 HCC (Training set, 60 patients/Test set, 40 patients)	CNN	Internal validation and testing	Accuracy: 66.81–77.50, AUC: 0.6865–0.7969	56.56–76.4/64.35–79.13
Aujay G, 2022 [80]	Prediction of response to TARE (evaluation of radiomics features associated with early response)	22 patients with HCC	Radiomics: four features associated with early response	No model development	AUC: 0.86–1 *across the four features*	75–100/86–100 *across the four features*

AUC: Area under the curve; CNN: Convolutional neural network; HCC: Hepatocellular carcinoma; LASSO: Least absolute shrinkage and selection operator; LR: Logistic regression; MRMR: Maximum relevance minimum redundancy; MWA: Microwave ablation; N.R.: Not reported; RF: Random forest; RSF: Random survival forest; SVM: Support vector machine; TACE: Transcatheter arterial chemoembolization; TARE: Transarterial radioembolization

used on CT image radiomics features by Liu et al. to develop AI-based prognostic risk factors for overall survival in patients treated with TACE and also help for the prediction of MVI [71]. Interestingly, these factors were shown to be independently associated with survival, but the study lacked external validation, which may limit generalizability [71]. Similarly, Zhang et al. built a DL signature derived from CT images of patients with HCC treated with TACE and sorafenib [72]. The nomogram, built by combining the DL signature and clinical features, showed good performances for prediction of overall survival.

Abajian et al. developed predictive models by using pretherapeutic MR images from 36 patients in combination with clinical parameters [73]. The resulting models could predict TACE treatment response with an accuracy of 78% [73]. Interestingly, other researchers tested an auto-context-based deep NN approach to detect and delineate different types of liver tissue after TACE (viable, necrosis) on multi-parameter MR images and demonstrated the feasibility of bypassing the time-consuming process of manually designing MRI-based features [74].

With a similar aim, Oezdemir et al. extracted handcrafted HCC microvascular features from CEUS images [75]. Although the model achieved an accuracy of 86%, these results require further evaluation due to the small sample size [75]. Finally, Liu et al. constructed and validated a DL radiomics-based model by using CEUS cine recordings. The model showed an AUC of 0.93 for prediction of response to TACE [76].

4.5. Thermal ablative therapies

Percutaneous thermal ablation is a therapeutic option in patients with early stage CHC (BCLC-0) [13–15,77]. Researchers evaluated treatment response to microwave ablation based on the ablative margin, by using MR images [78]. To reduce the registration errors due to breathing motion and heating-induced tissue deformation, they developed an unsupervised landmark-constrained CNN-based deformable image registration technique which could predict local tumor progression at two years with good accuracy [78]. Finally, another study showed that a CT-based peritumoral radiomics signature was more effective than a tumoral radiomics signature to predict early recurrence in HCC after curative tumor resection or ablation [79].

4.6. Transarterial radioembolization

One study evaluated radiomics using MRI data in the assessment of early response to ^{90}yttrium transarterial radioembolization in patients with locally advanced HCC [80]. They found four radiomics parameters predictors of early response with high sensitivities, outdoing other evaluation methods (mRECIST, RECIST) [80].

5. Current challenges for artificial intelligence applicability in healthcare

Although AI holds many promises for HCC management, and healthcare in general, deployment of AI algorithms in clinical settings remains very rare due to a number of challenges. First, there is the issue of regulation of AI models. AI tools, designed to assist in diagnosis and treatment of diseases, could be considered as medical devices and therefore should adhere to the respective regulations. Both the FDA and European commission have published plans on AI in medical device legislation to tackle this issue (https://futurium.ec.europa.eu/en/european-ai-alliance/document/artificial-intelligence-medical-device-legislation) [81]. There are also concerns regarding intellectual property, especially when changes or modifications are made overtime once the device is marketed. This also implies potential safety issues if the device evolves from its original form [82]. The lack of accuracy of AI models is another issue for applicability. Available health datasets can be subject to biases and data quality issues, which can arise during the collection process, in case of wrong labeling, in the context of lack of standardization and because of missing data. Indeed, large high-quality standardized health datasets are rare, and when using RCD, which are initially not collected for research purposes, there is a risk for the aforementioned limitations. Overfitting and spectrum biases are frequently encountered in AI-based models [83]. CNN, which is extensively used in radiological imaging-based models, is particularly vulnerable to overfitting [83]. Furthermore, standardized methods for AI-based data analysis or interpretation are still needed, as well as universal approaches to address missing data.

As the performance of AI models highly depends on the amount of data used for training, the availability of large datasets is crucial and data sharing should be encouraged. In this regard, one major issue is the “real-world” performance of AI and the need for post-approval validation of AI applications [11,84]. Sharing of individual-participant data from trials and studies could assist in constructing datasets of sufficient size and detail to appropriately train and validate AI models [85]. However, access to RCD for development of AI models, as well as data sharing of datasets, raises some ethical and privacy concerns for patients [86].

Another significant concern of integrating AI-based models in healthcare is the lack of interpretability. AI models are often described as “black-boxes” since there is little insight into how the model decides based on its input. To deal with this problem, “explainable AI”, which refers to a particular set of methods that allows users to interpret an AI model, is an active field of research. The main goal is to better interpret model outcomes. Interpretability is critical to build up the trust needed to convince doctors to rely on these CAD that might assist them in the future. All the more that the future implantation of these AI-based tools will raise the issue of liability regarding clinical decisions, especially in case of discrepancies between the physician and the tool. This might also involve legal considerations.

Finally, in order to fully demonstrate the role of AI in HCC clinical care, tailored prospective clinical trials are still needed. In that sense, the widely used SPIRIT and CONSORT guidelines have been extended to integrate the concept of interventions involving AI [87,88].

6. Conclusion

Many AI-based models have been developed with the aim to change and improve the way we care for patients with HCC. The utility of AI continues to evolve as an assistant for image interpretation, especially in the context of diagnosis and response to treatment. Although significant progress has been made during the last decade, improvements in HCC management are still critically needed. Existing studies involving imaging show that AI has a potential role for early detection of HCC, characterization of liver lesions and liver/tumor segmentation. Regarding HCC treatment, AI has the potential to both increase the efficiency and effectiveness of post-treatment evaluation as well as helping in treatment decision through pre-therapeutic prognostication. Now we must demonstrate that these approaches work in clinical settings, by comparing model performance to that of conventional staging systems, and further through the conduction of tailored prospective clinical trials involving AI-based interventions. Remains a great need to standardize and robustly evaluate AI algorithms in large-scale datasets that reflect the “real-world” heterogeneity and improve interpretability. Even if AI will most certainly play a role in the future of patient care alongside with the physician, only the latter is capable of understanding and considering patients’ needs, beliefs and wishes, to adjust the optimal individual treatment.

Human rights

The authors declare that the work described has been performed in accordance with the Declaration of Helsinki of the World Medical Association revised in 2013 for experiments involving humans.

Informed consent and patient details

The authors declare that this report does not contain any personal information that could lead to the identification of the patients.

Declaration of Competing Interest

The authors declare that they have no known competing financial or personal relationships that could be viewed as influencing the work reported in this paper.

Author contributions

All authors attest that they meet the current International Committee of Medical Journal Editors (ICMJE) criteria for Authorship. **Anna Pellat**: Conceptualization, Methodology, Formal analysis, Writing- Original draft preparation, Final draft approval; **Maxime Barat**: Conceptualization, Methodology, Formal analysis, Validation, Reviewing and Editing, Final draft approval; **Romain Coriat**: Conceptualization, Investigation, Supervision, Writing- Reviewing and Editing, Final draft approval; **Philippe Soyer**: Conceptualization, Supervision, Writing- Reviewing and Editing, Final draft approval; **Anthony Dohan**: Supervision, Conceptualization, Methodology, Writing – review & editing., Final draft approval.

Funding

This research did not receive any specific grant from funding agencies in the public, commercial, or not-for-profit sectors

References

[1] Kaul V, Enslin S, Gross SA. History of artificial intelligence in medicine. Gastrointest Endosc 2020;92:807–12.

[2] Lassau N, Bousaid I, Chouzenoux E, Verdon A, Balleyguier C, Bidault F, et al. Three artificial intelligence data challenges based on CT and ultrasound. Diagn Interv Imaging 2021;102:669–74.
[3] Min JK, Kwak MS, Cha JM. Overview of deep learning in gastrointestinal endoscopy. Gut Liver 2019;13:388–93.
[4] Yasaka K, Akai H, Kunimatsu A, Kiryu S, Abe O. Deep learning with convolutional neural network in radiology. Jpn J Radiol 2018;36:257–72.
[5] Milea D, Najjar RP, Zhubo J, Ting D, Vasseneix C, Xu X, et al. Artificial intelligence to detect papilledema from ocular fundus photographs. N Engl J Med 2020;382:1687–95.
[6] Noorbakhsh J, Farahmand S, Foroughi Pour A, Namburi S, Caruana D, Rimm D, et al. Deep learning-based cross-classifications reveal conserved spatial behaviors within tumor histological images. Nat Commun 2020;11:6367.
[7] Esteva A, Kuprel B, Novoa RA, Ko J, Swetter SM, Blau HM, et al. Dermatologist-level classification of skin cancer with deep neural networks. Nature 2017;542:115–8.
[8] Sung H, Ferlay J, Siegel RL, Laversanne M, Soerjomataram I, Jemal A, et al. Global cancer statistics 2020: GLOBOCAN estimates of incidence and mortality worldwide for 36 cancers in 185 countries. CA Cancer J Clin 2021;71:209–49.
[9] Rumgay H, Ferlay J, de Martel C, Georges D, Ibrahim AS, Zheng R, et al. Global, regional and national burden of primary liver cancer by subtype. Eur J Cancer 2022;161:108–18.
[10] Nakaura T, Higaki T, Awai K, Ikeda O, Yamashita Y. A primer for understanding radiology articles about machine learning and deep learning. Diagn Interv Imaging 2020;101:765–70.
[11] Soyer P, Fishman EK, Rowe SP, Patlas MN, Chassagnon G. Does artificial intelligence surpass the radiologist? Diagn Interv Imaging 2022;103:445–7.
[12] Liu Z, Wang S, Dong D, Wei J, Fang C, Zhou X, et al. The applications of radiomics in precision diagnosis and treatment of oncology: opportunities and challenges. Theranostics 2019;9:1303–22.
[13] EASL clinical practice guidelines: management of hepatocellular carcinoma. J Hepatol 2018;69:182–236.
[14] Marrero JA, Kulik LM, Sirlin CB, Zhu AX, Finn RS, Abecassis MM, et al. Diagnosis, staging, and management of hepatocellular carcinoma: 2018 practice guidance by the American association for the study of liver diseases. Hepatology 2018;68:723–50.
[15] Heimbach JK, Kulik LM, Finn RS, Sirlin CB, Abecassis MM, Roberts LR, et al. AASLD guidelines for the treatment of hepatocellular carcinoma. Hepatology 2018;67:358–80.
[16] Hanna RF, Miloushev VZ, Tang A, Finklestone LA, Brejt SZ, Sandhu RS, et al. Comparative 13-year meta-analysis of the sensitivity and positive predictive value of ultrasound, CT, and MRI for detecting hepatocellular carcinoma. Abdom Radiol 2016;41:71–90.
[17] Chou R, Cuevas C, Fu R, Devine B, Wasson N, Ginsburg A, et al. Imaging techniques for the diagnosis of hepatocellular carcinoma: a systematic review and meta-analysis. Ann Intern Med 2015;162:697–711.
[18] Bharti P, Mittal D, Ananthasivan R. Preliminary study of chronic liver classification on ultrasound images using an ensemble model. Ultrason Imaging 2018;40:357–79.
[19] Brehar R, Mitrea DA, Vancea F, Marita T, Nedevschi S, Lupsor-Platon M, et al. Comparison of deep-learning and conventional machine-learning methods for the automatic recognition of the hepatocellular carcinoma areas from ultrasound images. Sensors 2020;20:E3085.
[20] Virmani J, Kumar V, Kalra N, Khandelwal N. Neural network ensemble based CAD system for focal liver lesions from B-mode ultrasound. J Digit Imaging 2014;27:520–37.
[21] Schmauch B, Herent P, Jehanno P, Dehaene O, Saillard C, Aubé C, et al. Diagnosis of focal liver lesions from ultrasound using deep learning. Diagn Interv Imaging 2019;100:227–33.
[22] Yang Q, Wei J, Hao X, Kong S, Yu X, Jiang T, et al. Improving B-mode ultrasound diagnostic performance for focal liver lesions using deep learning: a multicentre study. EBioMedicine 2020;56:102777.
[23] Mao B, Ma J, Duan S, Xia Y, Tao Y, Zhang L. Preoperative classification of primary and metastatic liver cancer via machine learning-based ultrasound radiomics. Eur Radiol 2021;31:4576–86.
[24] Ren S, Qi Q, Liu S, Duan S, Mao B, Chang Z, et al. Preoperative prediction of pathological grading of hepatocellular carcinoma using machine learning-based ultrasomics: a multicenter study. Eur J Radiol 2021;143:109891.
[25] Ren S, Li Q, Liu S, Qi Q, Duan S, Mao B, et al. Clinical value of machine learning-based ultrasomics in preoperative differentiation between hepatocellular carcinoma and intrahepatic cholangiocarcinoma: a multicenter study. Front Oncol 2021;11:749137.
[26] Duron L, Savatovsky J, Fournier L, Lecler A. Can we use radiomics in ultrasound imaging? Impact of preprocessing on feature repeatability. Diagn Interv Imaging 2021;102:659–67.
[27] Ta CN, Kono Y, Eghtedari M, Taik Oh Y, Robbin ML, Barr RG, et al. Focal liver lesions: computer-aided diagnosis by using contrast-enhanced US cine recordings. Radiology 2018;286:1062–71.
[28] Huang Q, Pan F, Li W, Yuan F, Hu H, Huang J, et al. Differential diagnosis of atypical hepatocellular carcinoma in contrast-enhanced ultrasound using spatio-temporal diagnostic semantics. IEEE J Biomed Health Inform 2020;24:2860–9.
[29] Guo LH, Wang D, Qian YY, Zheng X, Zhao CK, Li XL, et al. A two-stage multi-view learning framework based computer-aided diagnosis of liver tumors with contrast enhanced ultrasound images. Clin Hemorheol Microcirc 2018;69:343–54.
[30] Wang W, Wu S-S, Zhang J-C, Xian M-F, Huang H, Li W, et al. Preoperative pathological grading of hepatocellular carcinoma using ultrasomics of contrast-Enhanced ultrasound. Acad Radiol 2021;28:1094–101.
[31] Mokrane F-Z, Lu L, Vavasseur A, Otal P, Peron J-M, Luk L, et al. Radiomics machine-learning signature for diagnosis of hepatocellular carcinoma in cirrhotic patients with indeterminate liver nodules. Eur Radiol 2020;30:558–70.
[32] Khan AA, Narejo GB. Analysis of abdominal computed tomography images for automatic liver cancer diagnosis using image processing algorithm. Curr Med Imaging Rev 2019;15:972–82.
[33] Krishan A, Mittal D. Ensembled liver cancer detection and classification using CT images. Proc Inst Mech Eng H 2021;235:232–44.
[34] Mao B, Zhang L, Ning P, Ding F, Wu F, Lu G, et al. Preoperative prediction for pathological grade of hepatocellular carcinoma via machine learning-based radiomics. Eur Radiol 2020;30:6924–32.
[35] Yasaka K, Akai H, Abe O, Kiryu S. Deep learning with convolutional neural network for differentiation of liver masses at dynamic contrast-enhanced CT: a preliminary study. Radiology 2018;286:887–96.
[36] Shi W, Kuang S, Cao S, Hu B, Xie S, Chen S, et al. Deep learning assisted differentiation of hepatocellular carcinoma from focal liver lesions: choice of four-phase and three-phase CT imaging protocol. Abdom Radiol 2020;45:2688–97.
[37] Li J, Wu Y, Shen N, Zhang J, Chen E, Sun J, et al. A fully automatic computer-aided diagnosis system for hepatocellular carcinoma using convolutional neural networks. Biocybern Biomed Eng 2020;40:238–48.
[38] Zhou J, Wang W, Lei B, Ge W, Huang Y, Zhang L, et al. Automatic detection and classification of focal liver lesions based on deep convolutional neural networks: a preliminary study. Front Oncol 2020;10:581210.
[39] Todoroki Y, Iwamoto Y, Lin L, Hu H, Chen YW. Automatic detection of focal liver lesions in multi-phase CT images using a multi-channel & multi-scale CNN. Annu Int Conf IEEE Eng Med Biol Soc 2019;2019:872–5.
[40] Ponnoprat D, Inkeaw P, Chaijaruwanich J, Traisathit P, Sripan P, Inmutto N, et al. Classification of hepatocellular carcinoma and intrahepatic cholangiocarcinoma based on multi-phase CT scans. Med Biol Eng Comput 2020;58:2497–515.
[41] Li W, Jia F, Hu Q. Automatic segmentation of liver tumor in CT images with deep convolutional neural networks. J Comput Com 2015;03:146.
[42] Sun C, Guo S, Zhang H, Li J, Chen M, Ma S, et al. Automatic segmentation of liver tumors from multiphase contrast-enhanced CT images based on FCNs. Artif Intell Med 2017;83:58–66.
[43] Chlebus G, Schenk A, Moltz JH, Ginneken BV, Hahn HK, Meine H. Automatic liver tumor segmentation in CT with fully convolutional neural networks and object-based postprocessing. Sci Rep 2018;8:15497.
[44] Chen L, Song H, Wang C, Cui Y, Yang J, Hu X, et al. Liver tumor segmentation in CT volumes using an adversarial densely connected network. BMC Bioinform 2019;20:587.
[45] Chen WF, Ou HY, Liu KH, Li ZY, Liao CC, Wang SY, et al. In-series U-net network to 3D tumor image reconstruction for liver hepatocellular carcinoma recognition. Diagnostics 2020;11:E11.
[46] Vivanti R, Szeskin A, Lev-Cohain N, Sosna J, Joskowicz L. Automatic detection of new tumors and tumor burden evaluation in longitudinal liver CT scan studies. Int J Comput Assist Radiol Surg 2017;12:1945–57.
[47] Kim J, Min JH, Kim SK, Shin SY, Lee MW. Detection of hepatocellular carcinoma in contrast-enhanced magnetic resonance imaging using deep learning classifier: a multi-center retrospective Study. Sci Rep 2020;10:9458.
[48] Bousabarah K, Letzen B, Tefera J, Savic L, Schobert I, Schlachter T, et al. Automated detection and delineation of hepatocellular carcinoma on multiphasic contrast-enhanced MRI using deep learning. Abdom Radiol 2021;46:216–25.
[49] Jansen MJA, Kuijf HJ, Veldhuis WB, Wessels FJ, Viergever MA, Pluim JPW. Automatic classification of focal liver lesions based on MRI and risk factors. PLoS One 2019;14:e0217053.
[50] Hamm CA, Wang CJ, Savic LJ, Ferrante M, Schobert I, Schlachter T, et al. Deep learning for liver tumor diagnosis part I: development of a convolutional neural network classifier for multi-phasic MRI. Eur Radiol 2019;29:3338–47.
[51] Zhen SH, Cheng M, Tao YB, Wang YF, Juengpanich S, Jiang ZY, et al. Deep Learning for accurate diagnosis of liver tumor based on magnetic resonance imaging and clinical data. Front Oncol 2020;10:680.
[52] Oestmann PM, Wang CJ, Savic LJ, Hamm CA, Stark S, Schobert I, et al. Deep learning-assisted differentiation of pathologically proven atypical and typical hepatocellular carcinoma (HCC) versus non-HCC on contrast-enhanced MRI of the liver. Eur Radiol 2021;31:4981–90.
[53] Wu Y, White GM, Cornelius T, Gowdar I, Ansari MH, Supanich MP, et al. Deep learning LI-RADS grading system based on contrast enhanced multiphase MRI for differentiation between LR-3 and LR-4/LR-5 liver tumors. Ann Transl Med 2020;8:701.
[54] Wang CJ, Hamm CA, Savic LJ, Ferrante M, Schobert I, Schlachter T, et al. Deep learning for liver tumor diagnosis part II: convolutional neural network interpretation using radiologic imaging features. Eur Radiol 2019;29:3348–57.
[55] Trivizakis E, Manikis GC, Nikiforaki K, Drevelegas K, Constantinides M, Drevelegas A, et al. Extending 2-D convolutional neural networks to 3-D for advancing deep learning cancer classification with application to MRI liver tumor differentiation. IEEE J Biomed Health Inform 2019;23:923–30.
[56] Oyama A, Hiraoka Y, Obayashi I, Saikawa Y, Furui S, Shiraishi K, et al. Hepatic tumor classification using texture and topology analysis of non-contrast-enhanced three-dimensional T1-weighted MR images with a radiomics approach. Sci Rep 2019;9:8764.
[57] Liang W, Shao J, Liu W, Ruan S, Tian W, Zhang X, et al. Differentiating hepatic epithelioid angiomyolipoma from hepatocellular carcinoma and focal nodular hyperplasia via radiomics models. Front Oncol 2020;10:564307.
[58] Guo D, Gu D, Wang H, Wei J, Wang Z, Hao X, et al. Radiomics analysis enables recurrence prediction for hepatocellular carcinoma after liver transplantation. Eur J Radiol 2019;117:33–40.

[59] Erstad DJ, Tanabe KK. Prognostic and therapeutic implications of microvascular invasion in hepatocellular carcinoma. Ann Surg Oncol 2019;26:1474–93.
[60] Jiang YQ, Cao SE, Cao S, Chen JN, Wang G-Y, Shi WQ, et al. Preoperative identification of microvascular invasion in hepatocellular carcinoma by XGBoost and deep learning. J Cancer Res Clin Oncol 2021;147:821–33.
[61] Ma X, Wei J, Gu D, Zhu Y, Feng B, Liang M, et al. Preoperative radiomics nomogram for microvascular invasion prediction in hepatocellular carcinoma using contrast-enhanced CT. Eur Radiol 2019;29:3595–605.
[62] Xu X, Zhang HL, Liu QP, Sun SW, Zhang J, Zhu FP, et al. Radiomic analysis of contrast-enhanced CT predicts microvascular invasion and outcome in hepatocellular carcinoma. J Hepatol 2019;70:1133–44.
[63] Song D, Wang Y, Wang W, Wang Y, Cai J, Zhu K, et al. Using deep learning to predict microvascular invasion in hepatocellular carcinoma based on dynamic contrast-enhanced MRI combined with clinical parameters. J Cancer Res Clin Oncol 2021;147:3757–67.
[64] Zhang Y, Lv X, Qiu J, Zhang B, Zhang L, Fang J, et al. Deep learning with 3D convolutional neural network for noninvasive prediction of microvascular invasion in hepatocellular carcinoma. J Magn Reson Imaging 2021;54:134–43.
[65] Wang G, Jian W, Cen X, Zhang L, Guo H, Liu Z, et al. Prediction of microvascular invasion of hepatocellular carcinoma based on preoperative diffusion-weighted MR using deep learning. Acad Radiol 2021;28(Suppl 1):S118–27.
[66] Dong Y, Zhou L, Xia W, Zhao XY, Zhang Q, Jian JM, et al. Preoperative prediction of microvascular invasion in hepatocellular carcinoma: initial application of a radiomic algorithm based on grayscale ultrasound images. Front Oncol 2020;10:353.
[67] Ji GW, Zhu FP, Xu Q, Wang K, Wu MY, Tang WW, et al. Machine-learning analysis of contrast-enhanced CT radiomics predicts recurrence of hepatocellular carcinoma after resection: a multi-institutional study. EBioMedicine 2019;50:156–65.
[68] Dohan A, Barat M, Coriat R, Soyer P. A step toward a better understanding of hepatocellular progression after transarterial embolization. Diagn Interv Imaging 2022;103:125–6.
[69] Morshid A, Elsayes KM, Khalaf AM, Elmohr MM, Yu J, Kaseb AO, et al. A machine learning model to predict hepatocellular carcinoma response to transcatheter arterial chemoembolization. Radiol Artif Intell 2019;1:e180021.
[70] Peng J, Kang S, Ning Z, Deng H, Shen J, Xu Y, et al. Residual convolutional neural network for predicting response of transarterial chemoembolization in hepatocellular carcinoma from CT imaging. Eur Radiol 2020;30:413–24.
[71] Liu QP, Xu X, Zhu FP, Zhang YD, Liu XS. Prediction of prognostic risk factors in hepatocellular carcinoma with transarterial chemoembolization using multimodal multi-task deep learning. EClinicalMedicine 2020;23:100379.
[72] Zhang L, Xia W, Yan ZP, Sun JH, Zhong BY, Hou ZH, et al. Deep learning predicts overall survival of patients with unresectable hepatocellular carcinoma treated by transarterial chemoembolization plus sorafenib. Front Oncol 2020;10:593292.
[73] Abajian A, Murali N, Savic LJ, Laage-Gaupp FM, Nezami N, Duncan JS, et al. Predicting treatment response to intra-arterial therapies for hepatocellular carcinoma with the use of supervised machine learning: an artificial intelligence concept. J Vasc Interv Radiol 2018;29 850-857.e1.
[74] Zhang F, Yang J, Nezami N, Laage-Gaupp F, Chapiro J, De Lin M, et al. Liver tissue classification using an auto-context-based deep neural network with a multi-phase training framework. Patch Based Tech Med Imaging 2018;11075:59–66.
[75] Oezdemir I, Wessner CE, Shaw C, Eisenbrey JR, Hoyt K. Tumor vascular networks depicted in contrast-enhanced ultrasound images as a predictor for transarterial chemoembolization treatment response. Ultrasound Med Biol 2020;46:2276–86.
[76] Liu D, Liu F, Xie X, Su L, Liu M, Xie X, et al. Accurate prediction of responses to transarterial chemoembolization for patients with hepatocellular carcinoma by using artificial intelligence in contrast-enhanced ultrasound. Eur Radiol 2020;30:2365–76.
[77] Young S, Rivard M, Kimyon R, Sanghvi T. Accuracy of liver ablation zone prediction in a single 2450MHz 100 Watt generator model microwave ablation system: an in human study. Diagn Interv Imaging 2020;101:225–33.
[78] An C, Jiang Y, Huang Z, Gu Y, Zhang T, Ma L, et al. Assessment of ablative margin after microwave ablation for hepatocellular carcinoma using deep learning-based deformable image registration. Front Oncol 2020;10:573316.
[79] Shan QY, Hu HT, Feng ST, Peng ZP, Chen SL, Zhou Q, et al. CT-based peritumoral radiomics signatures to predict early recurrence in hepatocellular carcinoma after curative tumor resection or ablation. Cancer Imaging 2019;19:11.
[80] Aujay G, Etchegaray C, Blanc J-F, Lapuyade B, Papadopoulos P, Pey MA, et al. Comparison of MRI-based response criteria and radiomics for the prediction of early response to transarterial radioembolization in patients with hepatocellular carcinoma. Diagn Interv Imaging 2022;103:360–6.
[81] Artificial intelligence/machine learning (AI/ML)-based software as a medical device (SaMD) action plan. https://www.fda.gov/medical-devices/software-medical-device-samd/artificial-intelligence-and-machine-learning-software-medical-device (2021, accessed 23 September 2022).
[82] Hwang TJ, Kesselheim AS, Vokinger KN. Lifecycle regulation of artificial intelligence– and machine learning–based software devices in medicine. JAMA 2019;322:2285–6.
[83] Park SH, Han K. Methodologic guide for evaluating clinical performance and effect of artificial intelligence technology for medical diagnosis and prediction. Radiology 2018;286:800–9.
[84] Dupuis M, Delbos L, Veil R, Adamsbaum C. External validation of a commercially available deep learning algorithm for fracture detection in children. Diagn Interv Imaging 2022;103:151–9.
[85] Chassagnon G, Dohan A. Artificial intelligence: from challenges to clinical implementation. Diagn Interv Imaging 2020;101:763–4.
[86] Krupinski EA. An ethics framework for clinical imaging data sharing and the greater good. Radiology 2020;295:683–4.
[87] Cruz Rivera S, Liu X, Chan AW, Denniston AK, Calvert MJ. Guidelines for clinical trial protocols for interventions involving artificial intelligence: the SPIRIT-AI extension. Nat Med 2020;26:1351–63.
[88] Liu X, Cruz Rivera S, Moher D, Calvert MJ, Denniston AK. Reporting guidelines for clinical trial reports for interventions involving artificial intelligence: the CONSORT-AI extension. Nat Med 2020;26:1364–74.